

## **Procedure Handouts:**

1. Audiometry/Tympanometry
2. Cerumen Removal
3. Fluorescein Staining/Corneal Abrasion Care
4. Incision and Drainage
5. Influenza Specimen Collection
6. Strep Swab Collection
7. Nurse Maid Elbow
8. Foreign Body Removal from Nose or Ear
9. Suturing and Staple care
10. Umbilical Cord Cauterization
11. Biopsy of skin/skin tag/tissue removal

## Audiometry

**Definition:** is the measurement of the range and sensitivity of a person's hearing

Two ways to hear sound:

Air conduction: Sound waves travel to the inner ear through the ear canal, eardrum, and bones of the middle ear

Bone conduction: Sound waves pass through the bones around and behind the ear

### **Types of Audiometry**

OAE-Newborn screening-physiologic response of the inner ear to brief clicks

ABR-Newborn screening-averaged number of responses of the brainstem to tones or clicks

Behavioral/hearing screening: raises hand to tones at fixed levels 20-25dB

### **Normal results:**

Ability to hear a whisper, normal speech or ticking watch

Tuning fork through bone and air conduction

Rhine and Weber Tests (2:1 air to bone conduction and equal sound in both ears)

Detailed audiometry: Able to hear tones from 250Hz-8,000Hz at 25dB or lower.

### **Tympanometry**

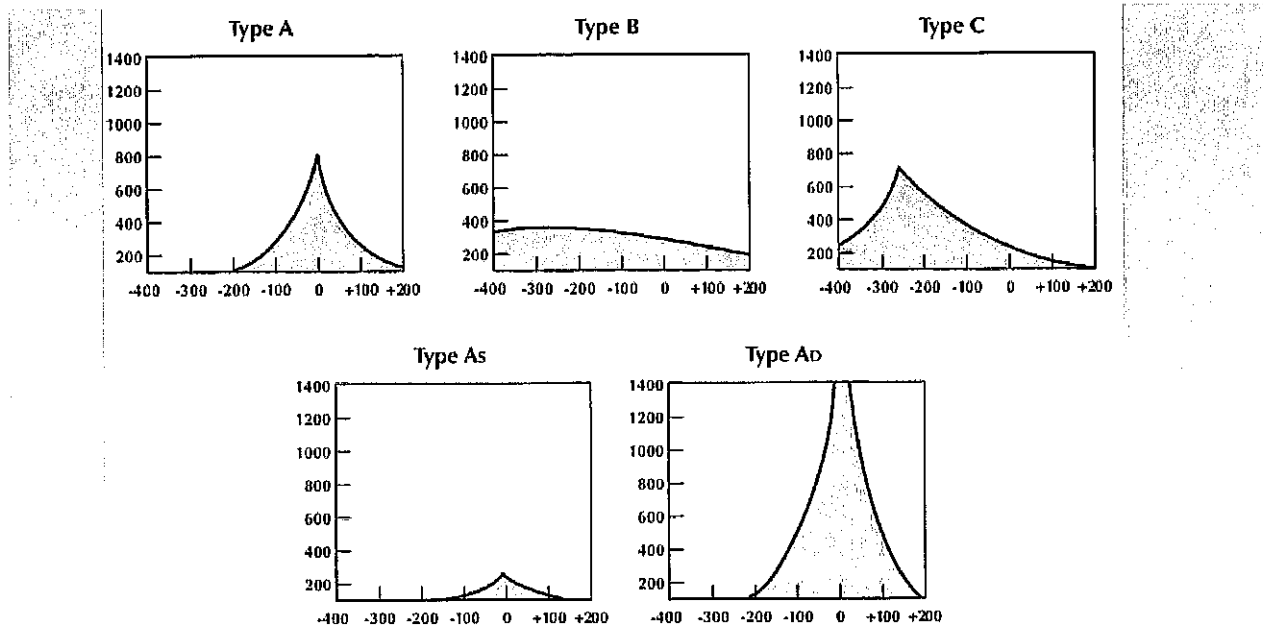
Evaluates the function of the middle ear by assessing the movement of the TM

-Applies pressure at -400 to +100 H<sub>2</sub>O pressure to the ear

-Use appropriate type and follow instructions on particular brand of tympanogram

-Warn child about feeling of pressure and pulling potentially on ear.

## Examples of Tympanograms:



Type	Implications
Type A	Normal tympanogram/ sensorineural hearing loss where conductive mechanism is normal.
Type B	Flat curve, no change in compliance with pressure changes. Seen in fluid in the middle ear.
Type C	Maximum compliance in negative pressure. Seen in eustachian tube obstruction.
Type As	Compliance is lower at or near ambient air pressure. Seen in otosclerosis or malleus fixation.
Type Ad	High compliance at or near ambient pressure. Seen in ossicular discontinuity.

## Cerumen Removal

### **Equipment**

Manual Removal: Currettes- Choose type based on consistency of the cerumen

Spoons/round/more firm-hard, dried cerumen vs Loops/oval/flexible-more soft and moist

Irrigation: Choose if unable to manually remove, the child is significantly uncooperative

Cannot be used on children with perforations or PE tubes

Microsuction: Older children (not able to get out other ways)

Typically not well tolerated in children

### **Procedure**

Position child with assistant and parent stabilizing the head

Manual Removal:

Perform otoscopic exam to confirm impaction

Using selected curette, reach through the opening of the otoscope OR

Use otoscope to assist in visualizing the cerumen

Do not insert cerumen spoon/loop past where you can see

Use a sweeping motion from top to bottom (softer cerumen on top and harder on bottom)

May want to consider ear wax softening agent if harder wax (such as Colace etc)

Irrigation:

Put warm water in the bottle (some institutions will use a bit of peroxide as well)

Place towel or pad to catch water on side irrigating

Place basin to receive water and cerumen below ear

Exam the ear to verify no perforations or known history of PE tubes that may be a contraindication

Gently insert tip of syringe or ear irrigation tube and insert water. Flush until cerumen returns

If get spray back, it may indicate cerumen dislodged that can be retrieved with curette.

Re-examine ear to see if cerumen impaction is resolve and repeat if needed.

**Post care:**

Discuss cerumen removal techniques and prevention such as not using q-tips, cleaning only external ear wax and possible cerumen softening agents.

## FLUORESCEIN EXAMINATION OF CORNEA AND CONJUNCTIVA

### INDICATIONS

- Unilateral foreign body sensation, hypersensitivity to light, excess tearing, or pain.
- Red eye
- Eye trauma
- Airbag deployment in auto accident
- Unilateral, persistent eye irritation in contact lens wearer
- Exposure to UV light from welding torch, sunlight, or tanning bed
- Mild chemical exposure to eye
- Neonates/infants persistent crying, unilateral tearing, hypersensitivity to light, or conjunctival inflammation
- Eye discharge in mask-ventilated newborn or heavily sedated/paralyzed adults on ventilator

### CONTRAINDICATIONS (refer to ophthalmologist)

- High-velocity eye injury i.e., metallic or nonmetallic fragments
- Hyphema, lens opacification, scleral tear, abnormal examination or irregularity of pupil
- Inflammation > 24 hours e.g. iritis, photophobia, or ciliary blush
- Exposure to caustic or acidic media
- Mild chemical exposure
- Ruptured globe
- Uncooperative patient

### EQUIPMENT

- Snellen chart at 20 feet, or equivalent visual acuity chart
- Topical ophthalmic anesthetic such as 0.5% proparacaine e.g., Alcaine, Kainair, Ophthaine, Fluress or a generic version has fluorescein and anesthetic in it, usually benoxinate.
- Sterile fluorescein sodium strips
- Bright white light source such as a penlight
- Cobalt-blue light source e.g., Wood's lamp
- An 8-to 10-power magnification lens or ophthalmoscope set at +20 to +40 diopter
- Sterile cotton-tipped applicators
- Isotonic ophthalmic irrigant such as normal saline
- Facial tissue

### TECHNIQUE

- Check and document visual acuity before instilling topical anesthetic
- Hand the patient a tissue and instill one to two drops of topical anesthetic into affected eye
- Inspect the affected eye and compare to opposite eye
- Flip upper lid into eversion
- Grasp lower lid, examine conjunctiva and entire eye for trauma, foreign body, or other sources of symptoms
- Instill fluorescein dye by moistening a sterile fluorescein strip with 1-2 drops of sterile saline or topical anesthetic, asking patient to look up, and gently touching the lower conjunctival sac for 3-5 seconds. After instilling the fluorescein, have patient blink a few times to remove excess tears, and blot them with tissue

- Inspect the cornea with magnification under a cobalt-blue light source. If the entire cornea is stained, irrigate eye again and re-examine. Abraded areas of cornea should remain high-lighted with fluorescein
- Make a drawing of the cornea for later reference
- If no cause of symptoms is found or 1 vertical streaking is found on cornea, suspect embedded conjunctival foreign body in the eyelid and examine the entire conjunctiva under cobalt-blue light.
- At this point, if no cause for the symptoms can be found, the eye should be examined under a slit lamp. For deep, dendritic, or central ulcerations or for ulcerations in which infection is suspected, refer to an ophthalmologist

#### **TREATMENT OF CORNEAL ABRASION**

##### **EQUIPMENT**

- Topical ophthalmic anesthetic
- Isotonic irrigant
- Ophthalmic antibiotic ointment i.e., bacitracin, ciprofloxacin, erythromycin, ofloxacin

##### **TECHNIQUE**

- Patient in supine position, irrigate eye with ophthalmic irrigant, patient's head turned toward affected side
- Instill 1-2 additional drops of local anesthetic
- Apply antibiotic ointment or drops (contact wearers e.g., ciprofloxacin, gentamicin, ofloxacin)
- Pain medication e.g., ophthalmic NSAIDs dose appropriate
- Re-examine eye in 24 hours and repeat visual acuity test
- Tetanus immunity verified or provided

##### **PATIENT EDUCATION**

- Instruct not to rub eyes
- Local anesthetic used during procedure wears off in a few minutes to hours
- Topical ophthalmic NSAIDs and/or moist compresses for pain relief
- Avoid extensive reading or watching television/digital devices
- Avoid driving until eye healed

## Incision and Drainage

**Equipment** — Assemble the following materials for the procedure:

- Sterile gloves, drapes, and 4 x 4 inch gauze
- Goggles or other eye protection (eg, surgical mask with integrated visor)
- Povidone-iodine solution
- Local anesthetic (eg, 1 or 2 percent lidocaine)
- 3 to 10 mL syringe and needle of 25, 27, or 30 gauge
- Culture swab
- Number 11 blade and scalpel holder
- Curved hemostats
- Forceps
- Scissors
- Needleless 30 to 60 mL syringe with 19 gauge IV catheter or needleless irrigation device with splash protection (eg, Zerowet Splashield)
- Basin with sterile saline solution
- Packing material (eg, iodoform or plain gauze packing tape)
- Dressing of choice

### PROCEDURE

**Incision** — After adequate analgesia is achieved, incise the skin with a number 11 scalpel blade.

Make a simple linear incision through the total length of the abscess with the incision conforming to the natural folds of the skin. Avoid cruciate or elliptical incisions because they can cause unsightly scars. If the abscess is in a cosmetic area or an area of skin tension, a stab incision may be used to limit tissue injury and scarring.

**Culture** — Prior to the emergence of community-acquired methicillin-resistant *Staphylococcus aureus* (cMRSA) infection, cultures were not routinely obtained when performing incision and drainage of a simple abscess, and when obtained did not typically change the care of otherwise healthy patients.

Wound cultures are still **not** necessary in healthy patients who will **not** receive antibiotics after abscess drainage.

However, given the increased prevalence of cMRSA infection and developing resistance patterns, we suggest that specimens for Gram stain, culture, and susceptibility testing be obtained if the patient will be treated with antibiotics and meets one of the following criteria:

- Severe, local infection (eg, extensive cellulitis, pilonidal cyst)
- Systemic signs of infection (eg, fever or hemodynamic instability)

- History of recurrent or multiple abscesses
- Failure of initial antibiotic treatment
- Extremes of age (young infants or the elderly)
- Immunocompromise

Wound culture may also be appropriate for otherwise healthy patients receiving antibiotics after abscess drainage who reside in regions where *Staphylococcus aureus* antibiotic susceptibility is unknown or rapidly changing.

For abscesses requiring incision and drainage, fluid for cultures may be obtained by swabbing purulent material. In selected patients, such as immunocompromised hosts or intravenous drug users, isolation of possible anaerobic organisms can be enhanced by needle aspiration with a syringe through appropriately cleaned (eg, with chlorhexidine) skin prior to incision and drainage.

**Probing and Irrigation** — After incision, probe the abscess cavity with a hemostat to break up loculations, identify foreign bodies, and ensure proper drainage. Do not probe with a gloved finger or scalpel. A gloved finger may be injured by a sharp foreign body, and a scalpel may cause tissue damage or create a false passage or fistula. Probing of the wound is painful and may require additional anesthesia.

Irrigate the abscess cavity copiously with isotonic saline solution until all visible pus is removed.

**Closure** — After incision, drainage, probing, and irrigation, we suggest that abscesses be left open to heal by secondary intention (secondary closure). In previously healthy adults without significant surrounding erythema >5 cm wide or signs of systemic infection, primary closure using nonabsorbable sutures and vertical mattress technique is an option.

Closure by secondary intention is the traditional approach to abscess management and is based upon the principle of avoiding the placement of foreign bodies in contaminated wounds. However, primary closure of abscesses is sometimes performed and evidence for this practice is as follows:

#### **Packing or drain placement**

**Indications** — After incision and drainage, we suggest packing any abscess cavity that meets any of the following criteria:

- Abscess >5 cm in diameter
- Pilonidal abscess
- Abscess in an immunocompromised or diabetic patient

In contrast to abscesses more than 5 cm in diameter, the benefit of packing smaller abscesses in otherwise healthy patients is debated and two small trials have failed to find a benefit for packing as follows:

**Technique** — After probing and irrigation, pack the cavity to prevent closure of the wound margins. Avoid packing the cavity too tightly, since excessive pressure may cause tissue necrosis.



Sterile gauze, iodoform gauze, or silver-containing hydrofiber (eg, Aquacel Ag) packing strips may be used to fill the abscess cavity. A tail of about 1 cm of packing can serve as a wick for drainage and facilitate subsequent removal of the packing material. The wound is left open and an absorbent dressing is placed over it. In an unblinded trial that compared silver-containing hydrofiber versus iodoform gauze packing in 92 adults receiving incision and drainage in an ED, silver-containing hydrofiber was associated with decreased pain at 48 to 72 hours and more rapid reduction in the abscess cavity size.

A Penrose drain or catheter may be preferred in patients with pilonidal abscesses and when follow-up is uncertain. In these circumstances, place a split Penrose drain or a balloon-tipped (eg, Foley) or flared-tipped (eg, Malecot) catheter into the cavity and secure it with an absorbable suture at the wound margin. Cut excess tubing approximately 2 cm above the skin surface. This technique is appropriate for any abscess, except ones located on the face

# Influenza Specimen Collection

## Nasopharyngeal Swab

- Materials**
- Sterile Dacron/nylon swab
  - Viral transport media tube (should contain 1-3 mL of sterile viral transport medium)

### Procedure

1. Tilt patient's head back 70 degrees.
2. Insert swab into nostril. (Swab should reach depth equal to distance from nostrils to outer opening of the ear.) Leave swab in place for several seconds to absorb secretions.
3. Slowly remove swab while rotating it. (Swab head nostrils with same swab.)
4. Place tip of swab into sterile viral transport media tube and snap/cut off the applicator stick.

## Nasopharyngeal/Nasal Aspirate

- Sterile suction catheter/suction apparatus
- Viral transport media tube (should contain 1-3 mL of sterile viral transport medium)

1. Attach catheter to suction apparatus.
  2. Tilt patient's head back 70 degrees.
  3. Insert catheter into nostril. (Catheter should reach depth equal to distance from nostrils to outer opening of ear.)
  4. Begin gentle suction. Remove catheter while rotating it gently.
  5. Place specimen in sterile viral transport media tube.
- Note: NP aspirate may not be possible to conduct in infants.*

## Nasopharyngeal/Nasal Wash

- Sterile suction catheter/suction apparatus
- Sterile normal saline

1. Attach catheter to suction apparatus.
  2. Tilt patient's head back 70 degrees.
  3. Insert several drops of sterile normal saline into each nostril.
  4. Insert catheter into nostril. (Catheter should reach depth equal to distance from nostrils to outer opening of ear.)
  5. Begin gentle suction. Remove catheter while rotating it gently.
  6. Place specimen in sterile viral transport media tube.
- Note: NP aspirate may not be possible to conduct in infants.*

## Deep Nasal Swab

- Sterile polyester swab (aluminum or plastic shaft preferred)
- Viral transport media tube (should contain 1-3 mL of sterile viral transport medium)

1. Tilt patient's head back 70 degrees.
2. While gently rotating the swab, insert swab less than one inch into nostril (until resistance is met at turbinates).
3. Rotate the swab several times against nasal wall and repeat in other nostril using the same swab.
4. Place tip of the swab into sterile sterile viral transport media tube and cut off the applicator stick.

## Combined Nasal & Throat Swab

- 2 dry sterile polyester swabs (aluminum or plastic shafts preferred)
- Viral transport media tube (should contain 1-3 mL of sterile viral transport medium)

1. Tilt patient's head back 70 degrees.
2. While gently rotating the swab, insert swab less than one inch into nostril (until resistance is met at turbinates).
3. Rotate the swab several times against nasal wall and repeat in other nostril using the same swab.
4. Place tip of the swab into sterile viral transport media tube and cut off the applicator stick.
5. For throat swab, take a second dry polyester swab, insert into mouth, and swab the posterior pharynx and tonsillar areas. (Avoid the tongue.)
6. Place tip of swab into the same tube and cut off the applicator tip.

## Packaging:

- Label the specimen on viral transport media tube and ensure cap on tube is tightly sealed. (Do not use a pencil or pen for labeling, as they can rub off or smear. Instead, use a bar code or permanent marker).
  - Fill out paperwork in accordance with state health department guidelines.
  - Include a frozen cold pack with the specimen(s).
  - Pack specimens in accordance with U.S. Department of Transportation regulations regarding shipment of biological substances, see [www.cdc.gov/oddpd/directives/regs/ps/index.htm](http://www.cdc.gov/oddpd/directives/regs/ps/index.htm).
- ### Storage:
- Specimens should be placed into sterile viral transport media and immediately placed on refrigerant gel packs or at 4 degrees Celsius (refrigerator) for transport to the state public health laboratory.
  - Keep specimens refrigerated (2-8 degrees Celsius, 26-46 degrees Fahrenheit) prior to shipping.

## Shipping:

- Ship specimens for testing as soon as possible.
- If delivery will be delayed for more than 2-4 days, specimen should be frozen at -70 degrees Celsius (-94 degrees Fahrenheit).
- Ensure specimen will be received by the public health laboratory during normal business hours.

## Considerations:

- A nasopharyngeal (NP) swab is the optimal upper respiratory tract specimen collection method for influenza testing. However, such specimens cannot be collected from infants and many older patients may not allow an NP specimen to be collected. Alternatively, a combined nasal and throat swab specimen or aspirate specimens can provide good influenza virus yield.
- Some influenza tests are approved only for use with certain kinds of respiratory tract specimens, so follow guidelines provided by test. Also, some tests (e.g., rapid influenza diagnostic tests) are only approved for certain kinds of respiratory tract specimens.
- For best results (i.e., highest influenza virus yield), collect respiratory tract specimens within four days of illness onset.
- Most sensitive and accurate tests for influenza virus detection are nucleic acid amplification tests (RT-PCR).
- Negative test results obtained from rapid influenza diagnostic tests (RIDTs) that detect influenza viral antigens do not exclude influenza virus infection in patients with signs and symptoms of influenza. A negative test result could be a false negative and should not preclude further diagnostic testing (such as RT-PCR) and starting empiric antiviral treatment.
- A surgical mask and gloves are recommended at a minimum for all procedures. For some patients and procedures, additional precautions may be indicated, see Standard Precautions at [www.cdc.gov/hpsc/2009/1920091a.pdf](http://www.cdc.gov/hpsc/2009/1920091a.pdf).



U.S. Department of  
Health and Human Services  
Centers for Disease  
Control and Prevention

### Steps to Collect a Throat Swab Specimen

- Wash hands thoroughly.
- Put on gloves, surgical mask and protective eye-wear.
- Have the patient facing a strong light to ensure the area to be swabbed is visible.
- Open the package containing the flocked swab and aseptically remove swab from package.
- Have the patient tilt their head backwards, open their mouth, and stick out their tongue.
- Use a wooden tongue depressor to hold the tongue in place.
- Without touching the sides of the mouth, use the sterile flocked swab to swab the the posterior nasopharynx and the tonsillar arches.
- Insert swab into sterile liquid amies transport system vial.
- Break the swab handle at scored breakpoint line.
- Replace cap and tighten to secure.
- Remove and aseptically dispose of gloves and mask.
- Label liquid amies vial with appropriate information.
- Deliver samples to laboratory for testing.

## Nurse Maid Elbow

### Key Characteristics:

Subluxation of the radial head

More common in younger children (<5 years)

Often occurs when the arm is suddenly tugged when stepping off curb, pulling of arm, or falls and catches self with arm

Can recur in children who have had a previous nurse maid elbow

### S/S:

Child refuses to bend or use the arm (holds arm in pronation and flexed)

### Evaluation:

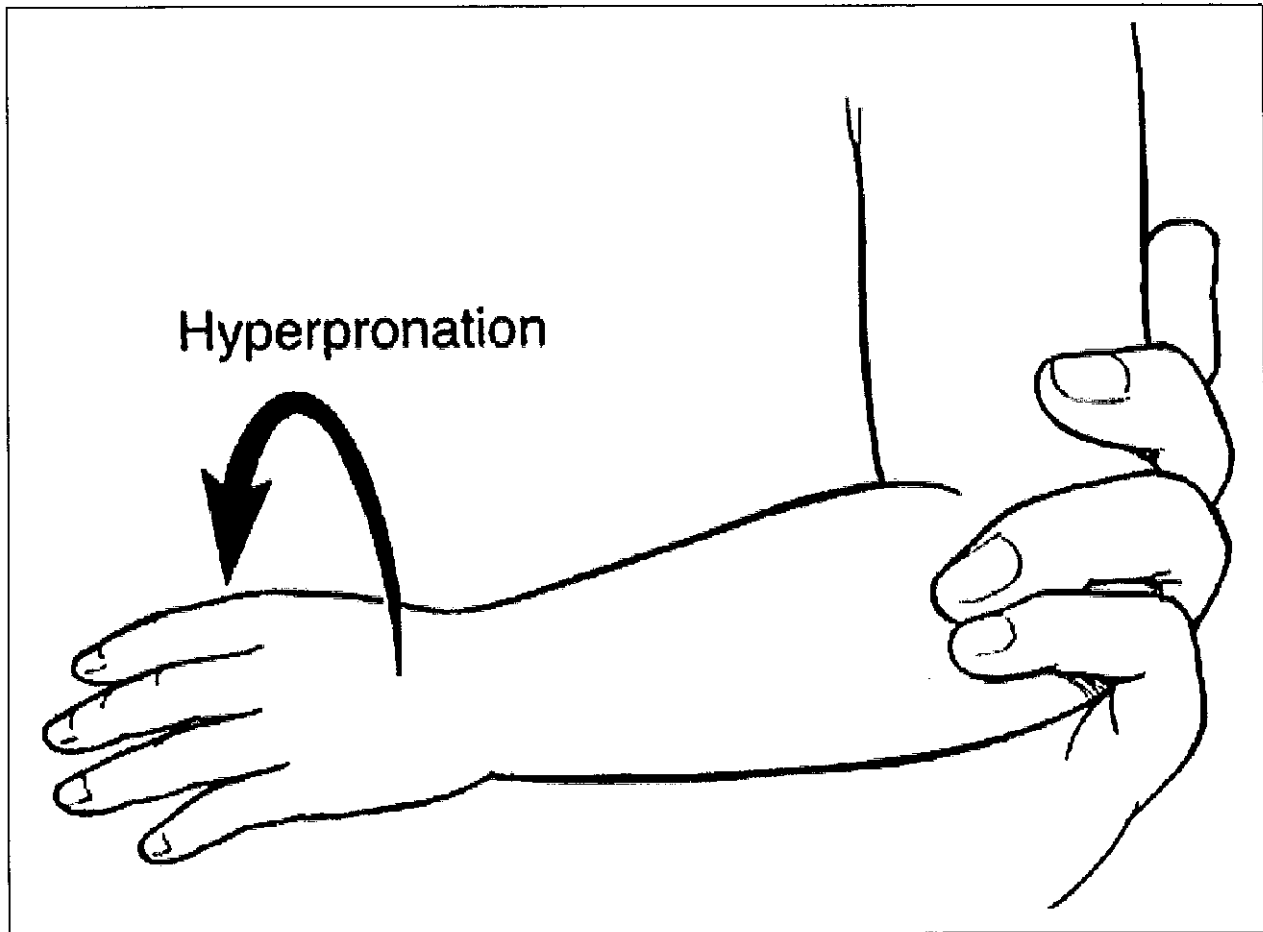
Consider x-ray to rule out fracture or other concerns

### Management: See two techniques on the next page

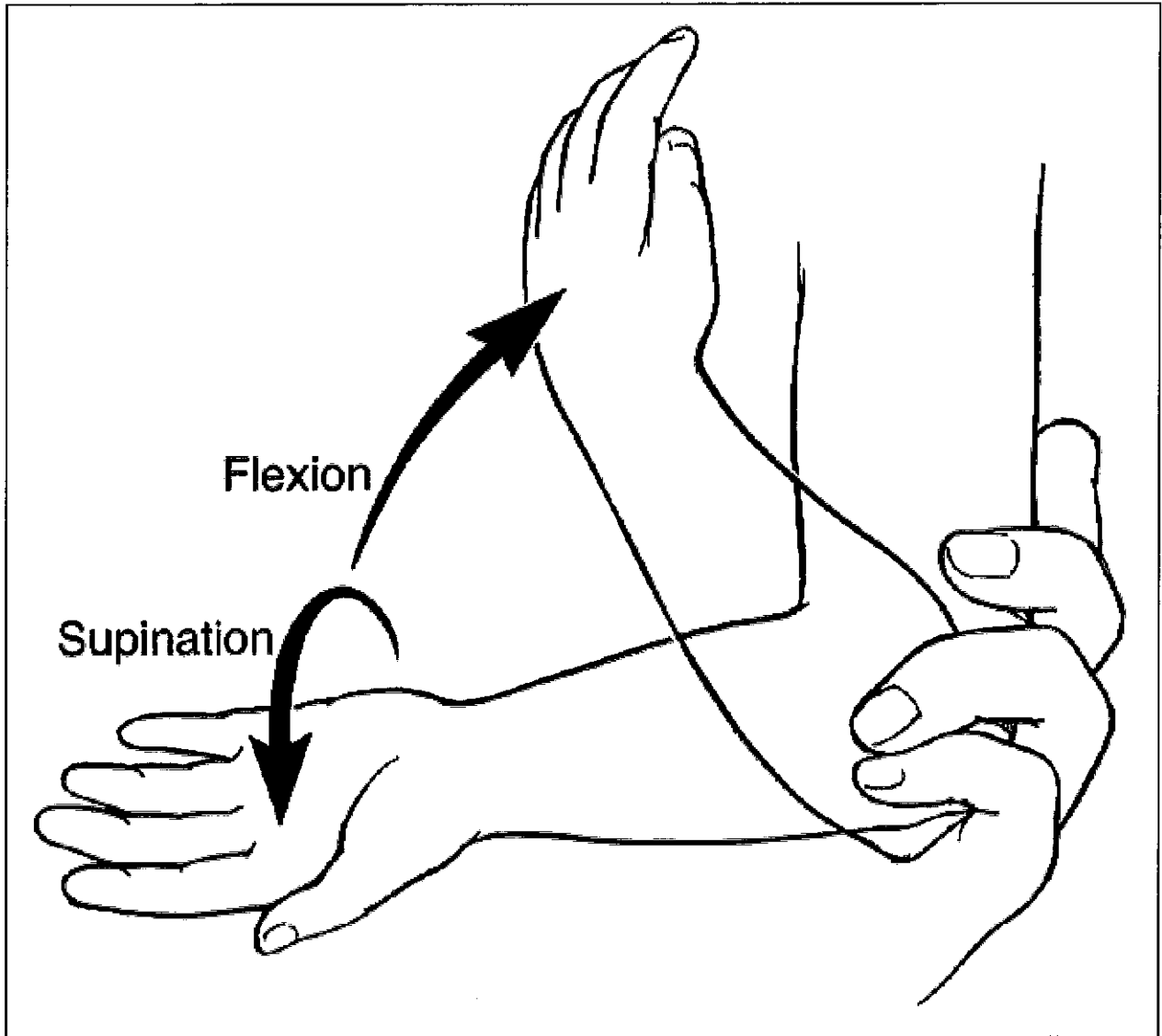
-If unsuccessful or no improvement after reduction within 15-30 mins consider fracture or other problem

-Should feel a pop or click when reduced

-When in doubt refer to ortho or ER if needed



Hyperpronation method- The examiner supports the child's arm at the elbow and places moderate pressure on the radial head with one finger. The examiner grips the child's distal forearm with the other hand and hyperpronates the forearm. A click may be felt by the finger over the radial head when the subluxation is reduced.



Supination-flexion maneuver technique- The examiner supports the child's arm at the elbow and exerts moderate pressure on the radial head with the thumb or one finger. With the other hand, the examiner holds the child's distal forearm, and then pulls with gentle traction. While maintaining traction, the examiner fully supinates the child's forearm and then fully flexes the elbow in one smooth motion. A click may be felt by the finger over the radial head or a pop may be heard by the examiner, when the subluxation is reduced.

## Foreign Body Removal from Nose or Ear

### **Indications/Contraindications:**

Known foreign body in the nose or ear that is retrievable

Contraindication: If the foreign body is behind middle turbinate or un-reachable or if the foreign body will cause damage to membranes (eg. button batteries need referral)

### **Equipment**

Small children may require sedation

Depth and surface of object will determine tool needed

Fibrous objects (cotton, plant material, bugs) can use alligator forceps

Smooth objects (beans, popcorn, seeds) can be removed with curette

Iron containing objects can be removed with magnet

Larger objects may be teased out with a fine 1mm right angle hook

May want to consider irrigation (for ears) or small foley like catheters for noses if available and unable to retrieve with other mechanisms

### **Procedure**

For ears:

Position child with assistance from parent or assistant

Visualize object to be removed with otoscope

Identify technique most appropriate and proximity/risk to TM rupture or other trauma

Gently remove object using equipment above as needed paying close attention to prevention of trauma

For noses:

Consider Angel Kiss: Occlude opposite nare and blow (parent can do this) in child's mouth forcefully to dislodge object)

If unsuccessful:

Extend child's head

Apply pressure on the tip of the nose in superior and posterior direction to visualize the nasal canal

Remove using equipment listed above as needed paying close attention to prevention of trauma.

**Post Care:** Monitor for bleeding or s/s of infection. Discuss prevention of Foreign bodies.

### Suturing:

Indications: Laceration that is large enough to not close on its own, would have a poor cosmetic outcome, procedure lacerations, or wounds that will have excessive bleeding unless closed.

### Contraindications:

- Nerve, tendon, ligament, muscle or other underlying tissue involved
- Dirty wounds
- Wounds that are older than 12-24 hours depending on the location and mechanism of injury
- Poor circulation to the area
- Complicating medical conditions such as diabetes, vascular disease ect.

### History and Physical Exam:

- How long ago? (>12 hours on body or >24 hours on face should not be close as general rule)
- Amount of blood loss?
- Last tetanus shot? (>10 years needs a booster, or >5 years if contaminated wound)
- Contamination/foreign body?
- Complicating medical conditions?
- PE: Signs of serious blood loss or hemodynamic compromise (stabilize patient)
- PE: Assess motor and sensory function including 2 point discrimination to the injury site (before and after closure)
- PE: Assess circulation distal to injury (before and after closure)
- PE: Identify size and depth of the lesion, visualize wound base to assure depth, underlying structures (might be damaged) and lack of foreign bodies

### Equipment:

Laceration tray, sterile gloves, anesthetic, irrigation kit (500cc NS), chlorhexidine prep (may vary based on institution), 4x4, procedure light, antibiotic ointment, goggles.

Procedure: See next pages (Reference: UW Emergency Medicine Interest group (ND). A guide to the basic suture workshop. Retrieved from:

[http://depts.washington.edu/uwemig/media\\_files/EMIG%20Suture%20Handout.pdf](http://depts.washington.edu/uwemig/media_files/EMIG%20Suture%20Handout.pdf)

### Complications:

Infection	Dehiscence
Scar formation	Unrecognized deep structure injury
Retained foreign body	Possible tetanus infection



*Local Anesthetics for Wound Care*

Agent	Concentration	Infiltration	Duration of block
lidocaine	1%, 2%	Immediate	30-60 min
lidocaine w/ epi <sup>®</sup>	1%	Immediate	60-120 min
bupivacaine	0.25%, 0.5%	Slower	240-480 min
Topical	Depending	5-15 min	20-30 min

<sup>®</sup> do not use epinephrine in ears, nose, penis, fingers, and toes!

*Absorbable Suture Materials*

Material	Structure	Tis. rxn	Strength	T ½	Uses
Gut	Natural	++++	++	5-7d	Mucosal closure, rare
Chromic Gut	Natural	++++	++	10-14d	Mucosa, perineal
Dexon	Braided	++	+++	25d	Sub Q closures
Vicryl	Braided	++	++++	28d	Mucosal closures
Maxon	Monofil	+	+++++	28-36d	Sub Q closures

*Non-absorbable Suture Materials*

Material	Structure	Tis. Rxn	Strength	Knot sec.	Uses
Silk	Braided	++++	++	++++	Easy to handle
Nylon	Monofil	++	+++	++	Common for skin cl.
Prolene	Monofil	+	++++	+	High memory, sub Q pull
Dacron	Braided	+++	++	++++	Good knot security

*Suture sizing by indication*

Location	superficial non-absorb	deep absorbable
Scalp, torso (chest, back, abdomen), extremities	3-0 to 5-0	3-0 or 4-0
Face, eyebrow, nose, lip	6-0	5-0
Ear, eyelid	6-0	n/a
Hand <sup>®</sup>	4-0 or 5-0	5-0
Foot or sole <sup>®</sup>	3-0 or 4-0	4-0
Penis	5-0 or 6-0	n/a

<sup>®</sup> deep sutures are to be avoided in the hands and feet unless being used to repair a tendon - they may increase the risk of wound infection.

## Anesthetization

Clean the area to be anesthetized with chlorhexidine or 1% betadine solution. Choose the appropriate anesthetic (for most cases this will be 1% lidocaine with or without epi). To buffer lidocaine, add bicarbonate to the solution in a 10:1 ratio. To buffer bupivacaine, add bicarbonate to the solution in a 30:1 ratio. Use bupivacaine for longer procedures, and mix with lidocaine for both rapid onset and longer duration. Draw up anesthetic in a 10cc syringe with an 18g needle. Change to 25g or 30g needle and remove all the air. Insert needle into subcutaneous tissue from within the wound margins and make a wheel under the skin. Continue along the entire wound margin to be repaired. Use plenty of anesthetic!

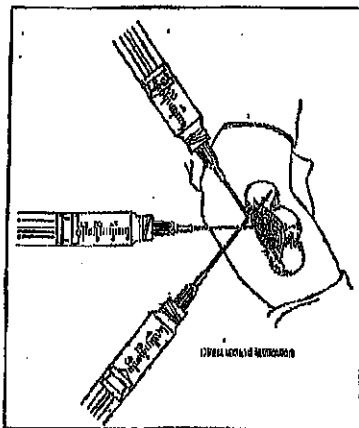


Fig. 2: local anesthesia  
(Wounds and Lacerations - Emergency Care and Closure)

## Wound Cleaning and Irrigation

Wearing eye protection, inspect wound for foreign bodies. Place chucks under the wound to collect drainage. Flush wound with copious amounts of normal saline. This can be done with a 30-60cc syringe with an 18g needle, IV bag with adapter, or special irrigation apparatus. Use a high pressure, direct stream in all areas of the wound. Avoid high pressure, however, on delicate tissues, such as the eye lids. A good rule of thumb is 100cc per 1cm of wound length. Once irrigated, switch to sterile gloves and cover the area with a sterile fenestrated drape. Explore the wound to assess the depth and presence of foreign bodies.

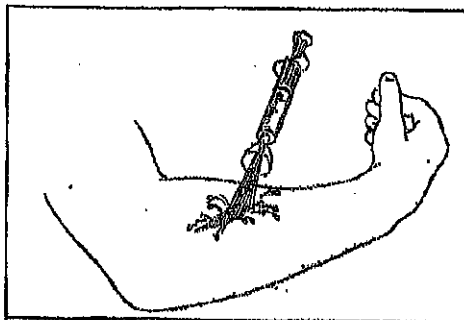


Fig. 3: high pressure wound irrigation  
(Wounds and Lacerations - Emergency Care and Closure)

## Basic Suturing Techniques

The simple interrupted technique is the predominant form of basic wound closure and the essential skill of the basic suturing workshop.

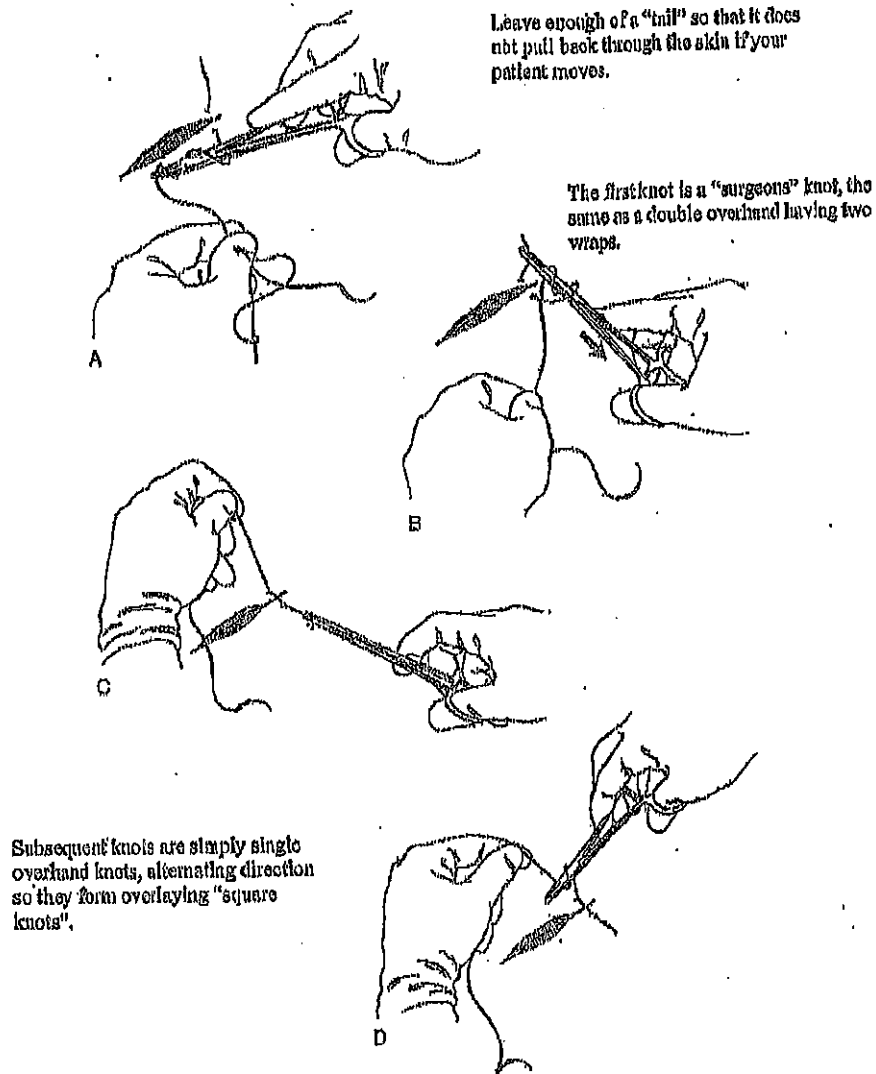


Fig. 4: simple interrupted suture technique  
(Wounds and Lacerations - Emergency Care and Closure)

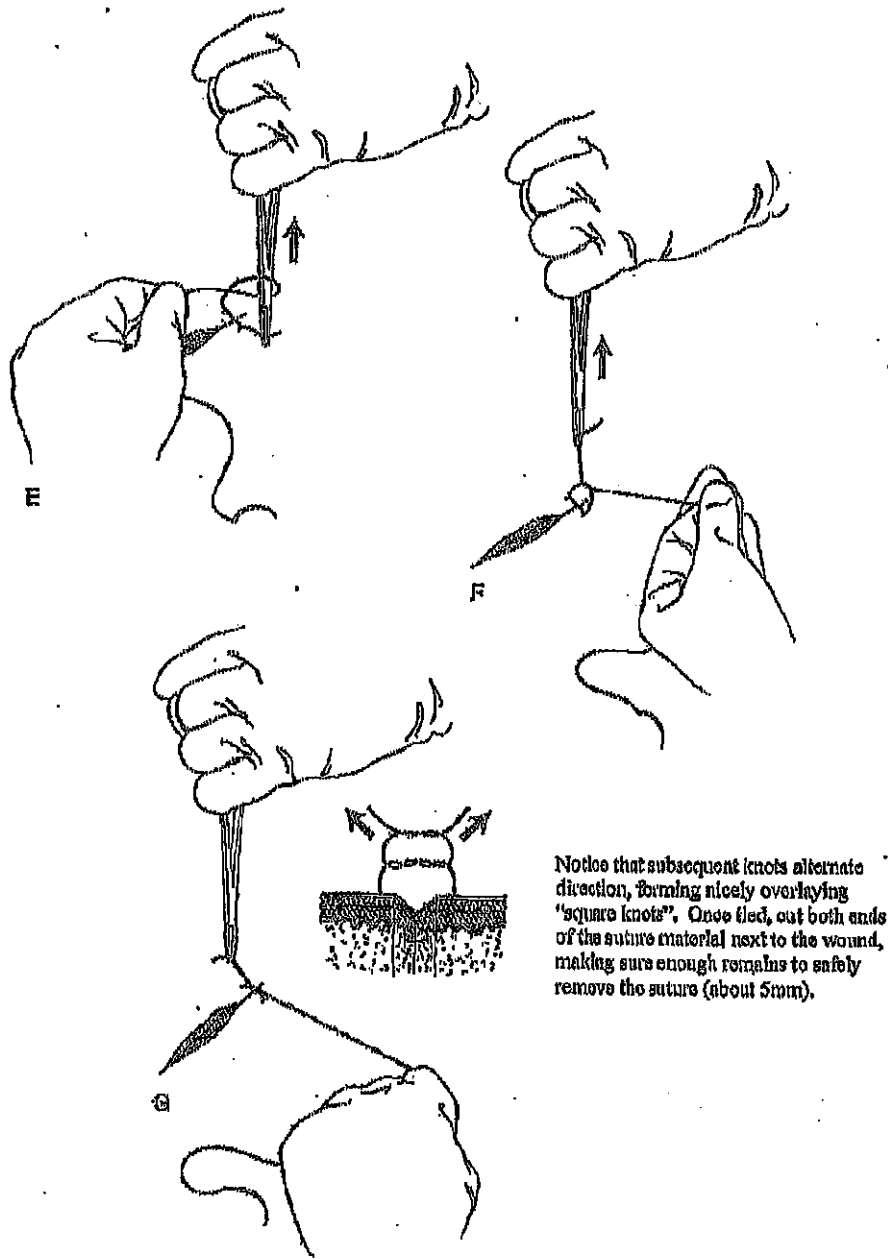


Fig. 4 cont.: simple interrupted suture technique  
 (Wounds and Lacerations - Emergency Care and Closure)

Larger wounds can be closed with a continuous simple suture technique. The first suture is made in the same manner as the simple interrupted, but subsequent sutures are placed without cutting the suture material. The final knot is made by taking a "bite" of the second to last pass through the tissue and tied in the usual fashion.

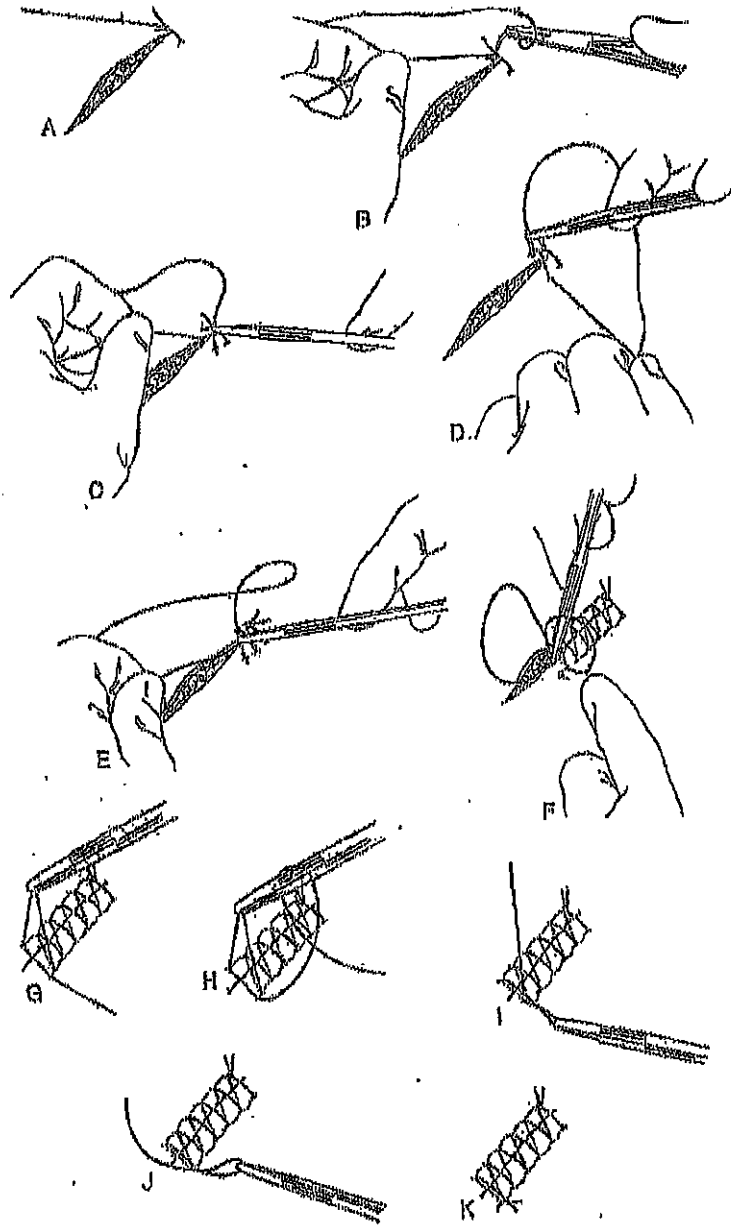
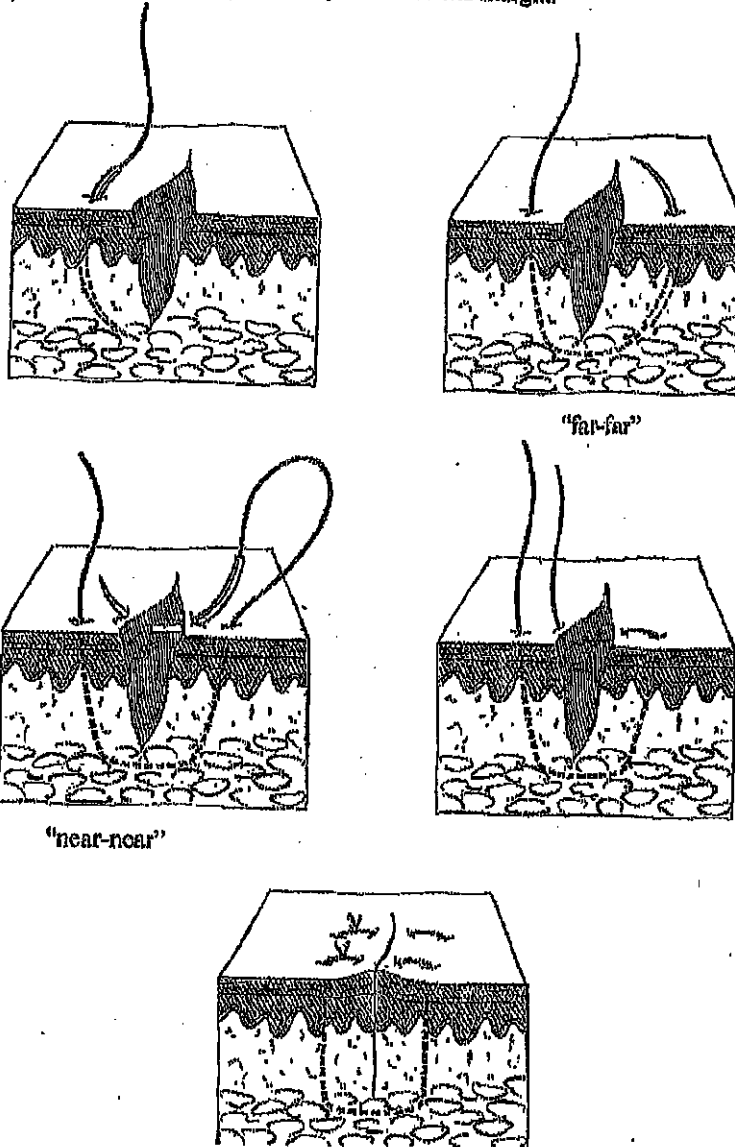


Fig. 5: continuous simple stitch  
(Wounds and Lacerations—Emergency Care and Closure)

The vertical mattress suture is ideal for equalizing high-tension forces across a wound edge. They are also helpful in areas where wound edge approximation and proper "tenting" is difficult. These can be intermixed with simple interrupted sutures and removed earlier to prevent scarring. A helpful mnemonic is "far-far ... near-near" meaning that you begin your first suture further away from the wound margin, and aim further away on your follow-through. The second pass through the tissue follows a similar tract, but closer (near-near) to the wound margin.



**Fig. 6: vertical mattress suture**  
 (Wounds and Lacerations - Emergency Care and Closure)

## Suture Spacing

Suture should be carefully placed to avoid shearing through the tissue wall. One should also avoid strangulating the tissue by tying the knot too tight. This can cause unnecessary scarring and tissue necrosis. The distance between sutures should be roughly  $\frac{1}{2}$  the length of the individual sutures. Place the first suture in the center of the wound if approximation will be difficult, continuing by closing the distance to the wound edges by  $\frac{1}{2}$  to minimize tension forces on the tissue wall. Notice that the knots are all on the same side. This aids with suture removal.

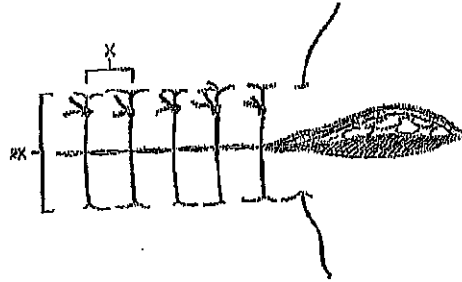


Fig. 7: appropriate suture placement  
(Wounds and Lacerations - Emergency Care and Closure)

## Tips

Be sure to place the needle to 90 degrees at the skin margin and rotate the needle through its arc while in the skin. On the opposite wound edge, be sure to run the needle through a symmetrical tract. This will insure level wound edge approximation. Failure to do so can result in worse approximation leading to poor wound healing and scarring. To facilitate this, keep the fingers free of the islet holes in the needle drivers.

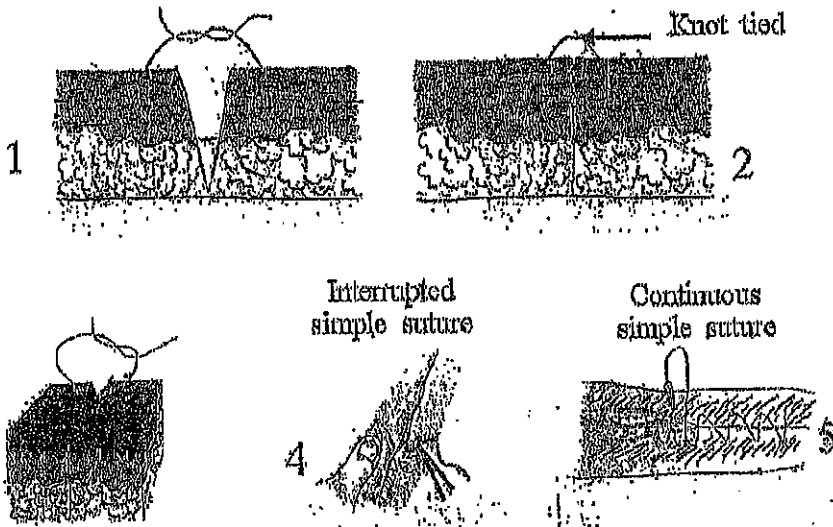


Fig. 8: putting it all together

## Patient Instructions and Follow-Up

### *Risks associated with anesthesia and laceration repair*

Complications of laceration repair include infection and wound dehiscence. A wound re-check should be scheduled for 24 to 48 hours after the wound closure if complications are likely. Other complications include scar formation, unrecognized deep-structure injury, and retained foreign body.

### *Tetanus shot*

Any open wound is potentially susceptible to tetanus infection. A booster should be administered if the last tetanus is >10 years old (assuming the patient has received the 3 shot primary series in the past). If the wound is contaminated with debris, a tetanus booster should be considered if the previous tetanus shot is >5 years old. In the event a patient has sustained a tetanus prone wound and has not received the primary 3 shot series, they will require tetanus immune globulin and must be initiated on the primary immunization series.

### *Wound care*

After the first 24-48 hours, patients should gently wash the wound with soap and water, dry it carefully, apply topical antibiotic ointment, and replace the dressing/bandages. Facial wounds generally only need topical antibiotic ointment without bandaging. Sunscreen spf 30 should be applied to the wound to prevent subsequent hyperpigmentation.

### *Suture removal*

Removing sutures is generally a quick and painless procedure. Removal time considers both the potential for scarring and the required tensile strength of the wound to withstand stressors.

Area	Removal Time
Face	3-5 days
Neck	4-6 days
Scalp	7-12 days
Upper extremity	8-14 days
Trunk	6-14 days
Extensor surface of hands	10 days
Lower extremity	14-28 days

### *When to RTC/ER*

Patients should be instructed to return to the clinic/ED if they note signs of infection (redness, heat, pain, puss, etc), inadequate analgesia, or suture complication. The latter may include suture strangulation or knot failure with possible wound dehiscence. It should be emphasized to patients that they return at the appropriate time for suture removal or complications may arise leading to further scarring or subsequent surgical removal of buried sutures.




# Summary

835

Table 2. SUTURE REPAIR OF BODY TISSUE INJURIES

Location	Anesthetic	Suture Material	Technique of Closure and Dressing	Suture Interval (d)	Warning
Scalp	Lidocaine 1% with epinephrine	3-0 or 4-0 Nonabsorbable monofilament	Interrupted in single or double layer in scalp—horizontal running if possible; not well controlled by simple closure	7-12	Failure to explore wound for foreign bodies; hemostasis furnished according to "usual" closure
Face	Lidocaine 1% with epinephrine or use field block	4-0 or 5-0 Synthetic absorbable or 6-0 nonabsorbable monofilament	If full-thickness laceration, layered closure by dermalis	6-8	Failure to recognize and examine for damage to underlying structures, i.e., facial nerve; possible distal hematoma formation according to proper or no dressing
Plum (ear)	Lidocaine 1% (field block)	6-0 Nonabsorbable monofilament or 6-0 synthetic absorbable	Cross-pull suturing with 6-0 synthetic absorbable; clean skin with povidone-iodine; layered closure—skin closure	4-6	Foreign body retention; infection
Eye/eyelid	Lidocaine 1% with epinephrine	4-0 or 5-0 Synthetic absorbable or 6-0 nonabsorbable monofilament	Layered closure	4-6	Foreign body retention; infection; if not fully closed, failure to examine for globe injury or to explore orbit fully to level of globe
Wound	Lidocaine 1%	6-0 Nonabsorbable monofilament	Single-layer horizontal mattress, interrupted or running	3-3	2 mm or greater misalignment of wound line; possible infection
Lip	Lidocaine 1% with epinephrine or use field block	4-0 or 5-0 Synthetic absorbable in mucosa, muscle, and subdermal layer; 6-0 nonabsorbable monofilament	Non-suture closures, muscle, and skin if through and through laceration; 6-0 suture	7-8 or allow to desolve	Inadequate closure and possible application in children for necessary procedure
Oral cavity	Lidocaine 1% with epinephrine or IV sedation (in children)	4-0 Synthetic absorbable	Simple interrupted or horizontal mattress layered closure if mucosa or tongue involved	7-8 or allow to desolve	Failure to appreciate implications of zone I or zone II injury; delay in wound management
Neck	Lidocaine 1% with epinephrine	4-0 Synthetic absorbable (intracutaneous) or 6-0 nonabsorbable monofilament	Two-layered closure for best cosmetic results	4-6	
Abdomen	Lidocaine 1% with epinephrine	4-0 Synthetic absorbable; 4-0 or 6-0 nonabsorbable monofilament	Single or layered closure	6-12	Failure to use good wound approximation or not fully assess and adequately follow up with further diagnostic procedure
Back	Lidocaine 1% with epinephrine	4-0 Synthetic absorbable; 4-0 or 6-0 nonabsorbable monofilament	Single or layered closure	6-12	Failure to appreciate possibility of zone I or II laceration injury
Chest	Lidocaine 1% with epinephrine	4-0 Synthetic absorbable; 4-0 or 6-0 nonabsorbable monofilament	Single or layered closure	6-12	Exploration of wound may cause tamponade or possible possibility of subcutaneous penetration in low chest wounds and potential tamponade in wounds that penetrate
Abdominally	Lidocaine 1% with epinephrine 1%	6-0 or 4-0 Synthetic absorbable (intracutaneous); 4-0 or 6-0 nonabsorbable monofilament	Single-layered closure in abdomen, although layered or running 6-0 closure may give better cosmetic result; every abdominal wound is zone I injury	6-14	Failure to do adequate exploration before closure; failure to explore wound fully after abdominal exploration; failure to return body to its normal position at time of injury
Hand and foot	Lidocaine 1% or field block with 2% lidocaine or 0.25% bupivacaine	4-0 or 6-0 Nonabsorbable monofilament	Single-layered closure only with simple or horizontal mattress interrupted suture, at least 8 mm long cut wound edges; horizontal mattress suture should be used if wound tension on wound edges; apply splint if wound over a joint	7-12	Loss of outline for hand, foot, and leg; if not through thick mattress suture; additional because of failure to place skin between epidermal and motor
Hand/foot	Lidocaine 2% or bupivacaine 0.25% digital nerve block	6-0 Synthetic absorbable	Simple, mattress placement to distal even edges; skin closure with horizontal or vertical suture for best cosmetic result; to prevent edema	Allow to absorb	



Good youtube video on various suturing techniques:  
<https://www.youtube.com/watch?v=oi4fr4cMh70>

## Umbilical Cord Cauterization

### Indications:

Umbilical cord granulation tissue or persistent oozing from umbilical stump after cord has fallen off the baby (usually 1-2 weeks of life)

### Contraindications:

Active significant bleeding or s/s of infection of the umbilical cord stump

Don't use in highly visible area because silver nitrate can cause permanent staining/tattooing

### Equipment:

Silver Nitrate solution with small swab

Silver Nitrate infused swab-most commonly used and available

### Silver Nitrate

Silver ion cause proteins to precipitate which occludes blood vessels

- Silver salts stain the tissue black because of the deposition of reduced silver
  - Usually resolves in 2-3 weeks but can cause permanent staining

### Technique:

Clean area of application to remove debris or blood

Gently moisten the tip of the silver nitrate swab


Place silver nitrate swab on granulation tissue being careful to avoid healthy tissue surrounding the wound

### Post care:

Monitor for resolution of oozing and granulation tissue (may require reapplication if not resolving in 1-3 days). Expect black eschar within 24 hours of treatment

Monitor site for s/s of infection or excessive bleeding

Warn parents about staining of skin and possibly clothes



# **Punch Biopsy of the Skin**

*Am Fam Physician.* 2002 Mar 15;65(6):1167-1168.

## **What is punch biopsy?**

Punch biopsy is a commonly performed diagnostic procedure on abnormal skin growths or skin tumors. It is performed using a local anesthetic (numbing medicine). A pencil-like instrument is used to remove a small, thin cylinder of tissue. The small hole in the skin then may be sutured (stitched) closed.

## **What happens to the biopsy specimen once it is removed?**

After removal, the biopsy specimen is sent to the laboratory for further evaluation. The specimen is examined under a microscope by a subspecialist doctor known as a pathologist. The pathologist is trained to correctly identify the cells of various skin growths, which will assist your doctor in selecting the proper treatment.

## **Are there any complications after punch biopsy?**

Complications are uncommon following this simple procedure but can occur with any surgical procedure. Some of the complications associated with punch biopsy include local bleeding and bruising, pain, infection, allergic reaction to the numbing medicine used in the procedure, or damage to the structures beneath the skin site (such as an artery or a nerve). Your doctor will take care to reduce the likelihood of these rare problems.

## **What happens to the site where the piece of skin was removed?**

The biopsy site may be sutured (stitched) closed, depending on the size of the skin defect. The area often heals with a small scar. Your doctor may ask you to return in 5 to 14 days for removal of the stitches. You will be given instructions on how to help the biopsy site heal. The results of the biopsy evaluation will determine if further treatment of the skin site will be needed.

## **How long before I will receive the results of the biopsy evaluation?**

The biopsy results usually are available in one to two weeks. Your doctor's office will notify you of the results. You do not need to call the office in the first two weeks after the procedure. Sometimes the doctor will review the results with you at the follow-up (stitch removal) visit. If 1 month goes by and you have not heard from your doctor, call the office for the results of the biopsy.

## Following Punch Biopsy of the Skin

1. Immediately after removal of the skin biopsy specimen and closure of the biopsy site, your doctor will apply antibiotic ointment and a bandage to the site. Continue to apply antibiotic ointment to the wound until it is completely healed. The antibiotic ointment Mycitracin Plus is recommended because it contains numbing medicine in addition to the antibiotic.
2. You can remove the bandage at any time, but you may prefer to keep the wound covered. Keeping the site covered with a bandage may prevent rubbing at the site and will also keep the antibiotic ointment off your clothing.
3. If the biopsy site begins to bleed, apply direct pressure for 10 minutes. If it continues to bleed, call your doctor.
4. If you experience discomfort at the biopsy site, you can take ibuprofen (brand names: Advil, Motrin, Nuprin), three 200-mg tablets 3 times a day with food, or acetaminophen (brand name: Tylenol), two 325-mg tablets every 6 hours.
5. Skin infection can follow any surgical procedure. If you develop increased pain, redness, pus or swelling at the biopsy site, call your doctor.
6. Your doctor will notify you of the time for suture (stitch) removal, usually about 5 to 14 days following the procedure. Sometimes your doctor may have used only one stitch to close a punch biopsy site. If the stitch falls out and the wound is not gaping open, you can call and cancel your follow-up visit.
7. Most doctors use the suture removal visit to discuss with you the pathology results of the biopsy, if they are available. It usually takes 1 to 2 weeks for your doctor to receive the results of your biopsy. The doctor's office will contact you with the results. If 1 month goes by and you have not heard from your doctor's office, call to check on the biopsy results.

This handout is provided to you by your family doctor and the American Academy of Family Physicians. Other health-related information is available from the AAFP online at <http://familydoctor.org>.

## SORT: KEY RECOMMENDATIONS FOR PRACTICE

Clinical recommendation	Evidence rating	References	Comments
Whenever possible, lesions should be excised for diagnostic purposes using narrow margins.	C	<u>4, 5, 22</u>	Consensus guidelines
Punch or superficial shave biopsies may be more appropriate in carefully selected clinical circumstances (e.g., for large lesions, when melanoma suspicion is low) because of their potential effects on staging and prognosis.	C	<u>3, 7, 9-13, 16</u>	Consensus guidelines
A suspected melanoma should be excised using a 1- to 3-mm margin.	C	<u>3, 4</u>	Consensus guidelines
The type of biopsy performed does not influence survival rates in patients with melanoma.	B	<u>5, 10-12, 14-16</u>	Total of 5,240 patients in seven outcome case-control series

A = consistent, good-quality patient-oriented evidence; B = inconsistent or limited-quality patient-oriented evidence; C = consensus, disease-oriented evidence, usual practice, expert opinion, or case series. For information about the SORT evidence rating system, go to <http://www.aafp.org/afpsort.xml>. <http://www.aafp.org/afp/2011/1101/p995.html>

### Indications for Skin Biopsy

Indication	Clinical presentation	Possible diagnosis	Biopsy technique
Diagnosis	Rashes or blisters involving dermis	Drug reaction, cutaneous lymphoma, deep tissue infection, erythema multiforme, Kaposi sarcoma, lupus erythematosus, pemphigoid, pemphigus, vasculitis	Partial/perilesional punch
	Processes involving the subcutis	Erythema nodosum, panniculitis	Elliptical excision, saucerization
Diagnosis and treatment	Atypical moles and pigmented lesions	Dysplastic nevi, malignant melanoma	Elliptical excision; saucerization; punch for 1- to 4-mm lesions with 1- to 3-mm margins

Adapted with permission from Alguire PC, Mathes BM. Skin biopsy techniques for the internist. *J Gen Intern Med.* 1998;13(1):47

### **Type of Suture and Timing of Removal by Location**

<b>Location</b>	<b>Type of suture*</b>	<b>Timing of suture removal (days)</b>
Arms	4-0	7 to 10
Face	5-0 or 6-0	3 to 5
Hands or feet	4-0 or 5-0	10 to 14
Legs	4-0	10 to 14
Palms or soles	3-0 or 4-0	14 to 21
Scalp	4-0	7 to 10
Trunk	3-0 or 4-0	10 to 14

---

\*—Using polypropylene (Prolene), silk, or nylon.

### **Identifying High-Risk Lesions for Malignancy**

ABCDE system

Geometric Asymmetry in two axes

Irregular Border

At least two different Colors in lesion

Maximum Diameter > 6 mm

Evolution of lesion

Glasgow 7-point checklist

Major features

Change in size of lesion

Irregular border

Irregular pigmentation

Minor features

Inflammation

Itch or altered sensation

Lesion larger than others

Oozing and crusting

---

Adapted from Scottish Collegiate Guidelines Network. Cutaneous melanoma. A national clinical guideline. <http://www.sign.ac.uk/pdf/sign72.pdf>.

### **Dressing and Care of Biopsy Site**

Clean area after hemostasis is achieved.

Cover with petrolatum and sterile dressing.

Send tissue to pathology in formalin; if specimen is large enough and there is high suspicion for malignancy, consider suture tagging an area for pathologist.

Give discharge instructions; keep area covered and dry for 24 hours (punch biopsies) or covered and moist for at least one week (shave biopsies).

Complications are rare; bleeding can be managed with pressure, suture, or cautery; if infection occurs, it usually appears within three days after biopsy and can be treated with suture removal or oral antibiotics.

---